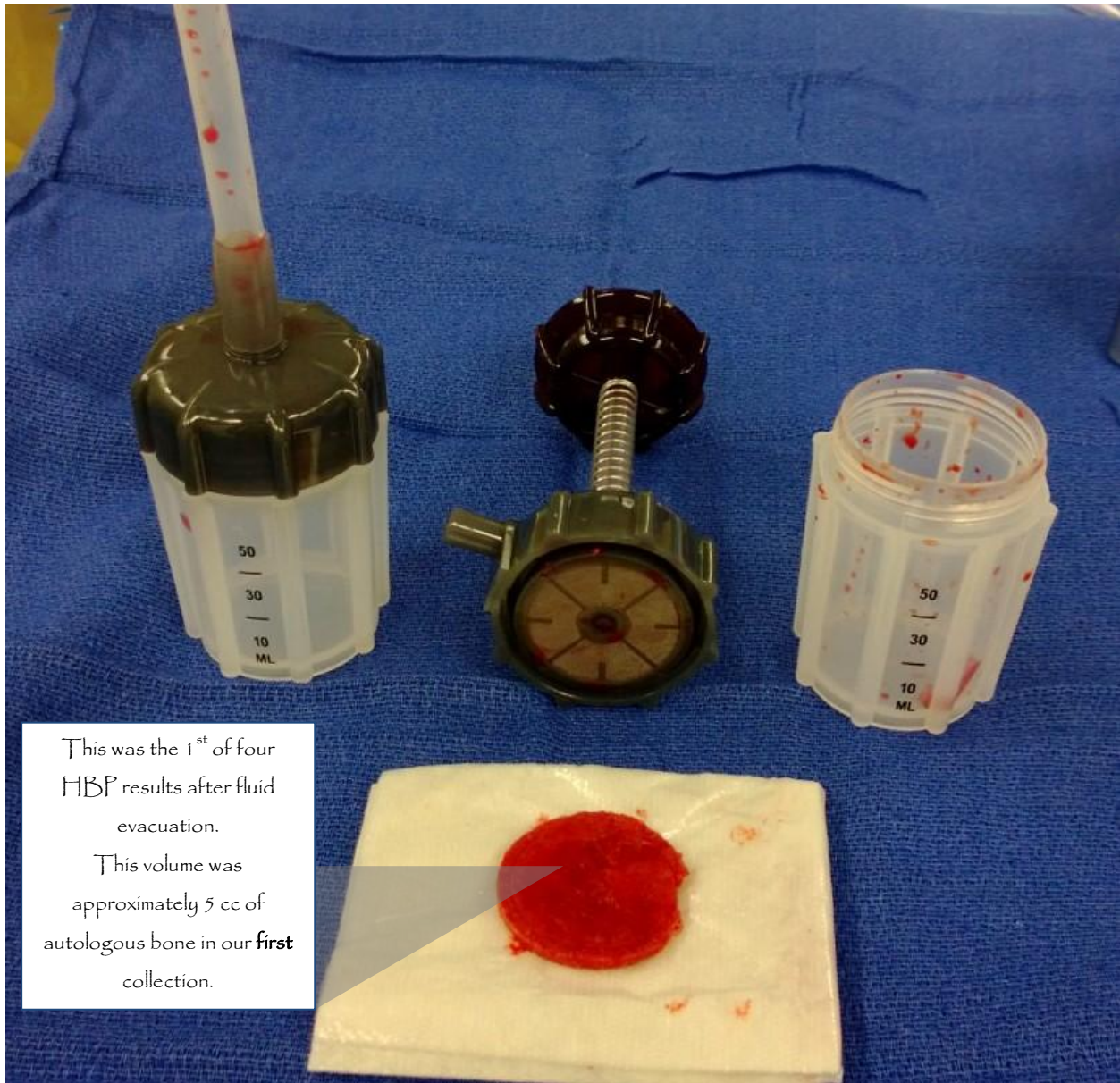


# HENSLER X SURGICAL

## Anterior Cervical Microdiscectomy and Fusion (3 level)



This was the 1<sup>st</sup> of four HBP results after fluid evacuation.

This volume was approximately 5 cc of autologous bone in our **first** collection.

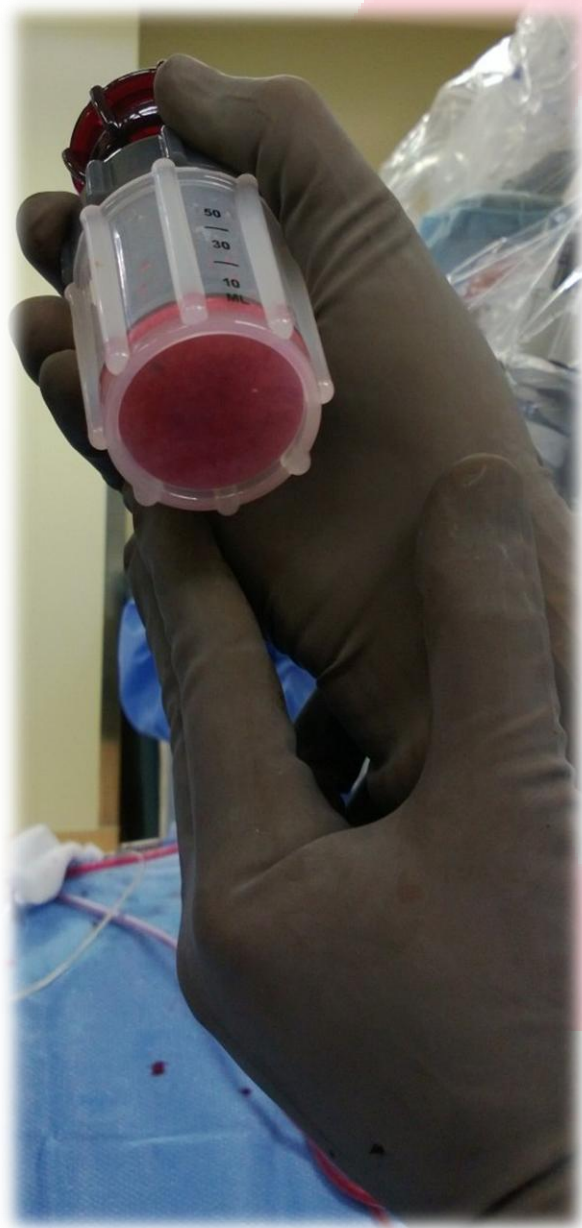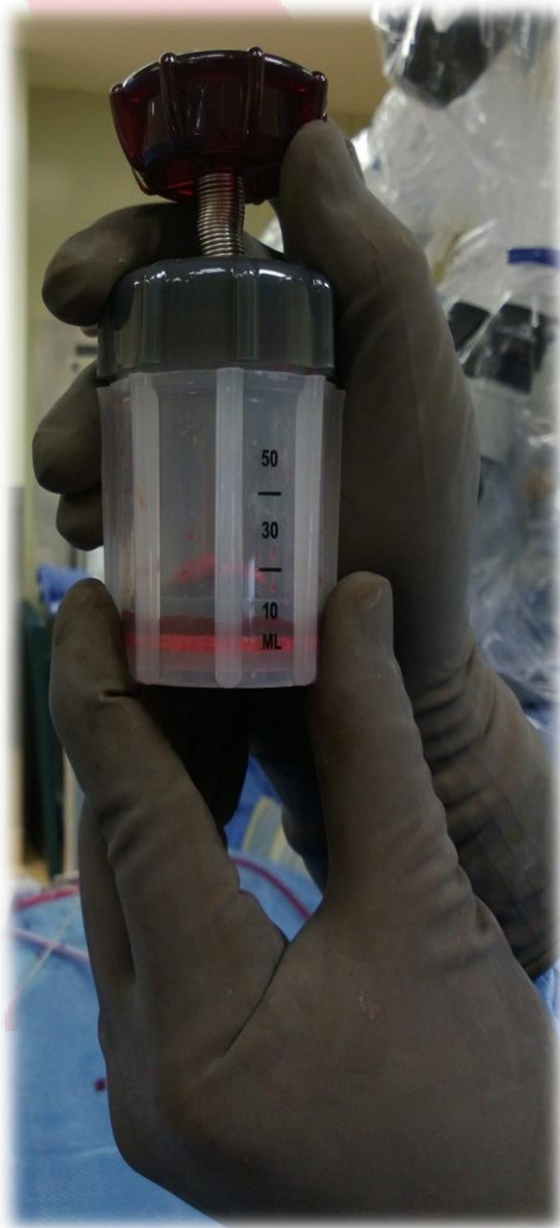
### Points of Interest:

- After 2-3 presses and evacuating the blood, the bone was placed onto a Telfa pad.
- The bone collected filled all 3 implants with left over autologous bone.
- We used a 30mm cutting burr for this case.
- The case yielded 4 rounds of separation. The container is 80cc in volume. **Irrigation** aids in thinning the blood and the collection of bone using the high speed drill.

# HENSLER X SURGICAL

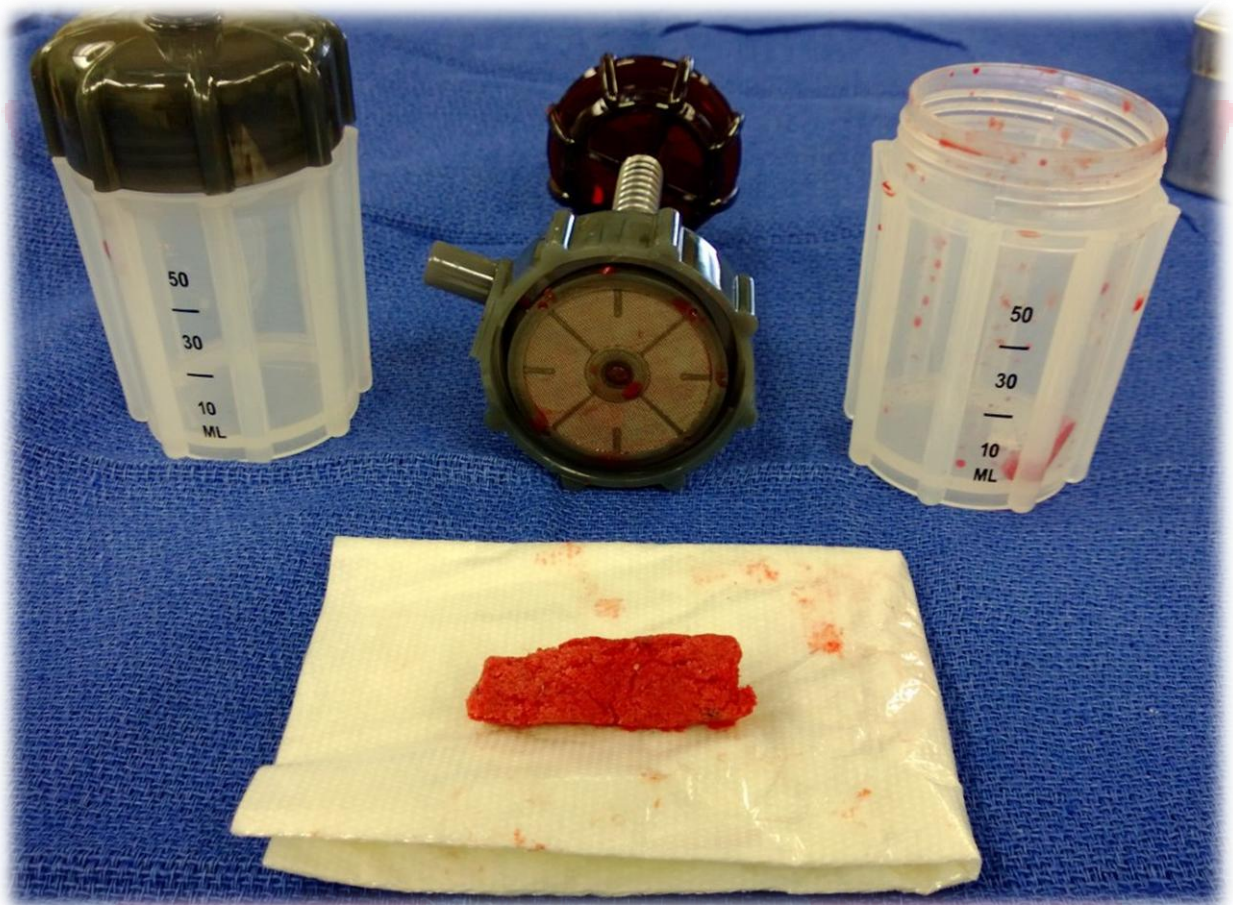
Anterior Cervical Microdiscectomy and Fusion (3 level)

Direct Visualization of Autologous bone



# HENSLER X SURGICAL

## Anterior Cervical Microdiscectomy and Fusion (3 level)



- At the end of the case, this was the **FINAL** results of all 4 collections.
- The amount was approximately 9-10 cc of autologous bone, respectively.
- There was left over bone after packing all three implants.
- No synthetic or additive was required.
- Cost savings and fusion optimization achieved.